MSSA Bacteremia and Mitral Valve Endocarditis Secondary to Infected Estradiol Vaginal Ring

Todd Looney[1], MD; Erik Anderson[2], MD; Lindsey Prescher[3], DO; Hampton Crimm[1], MD

[1]Department of Cardiology; [2]Department of Internal Medicine; [3]Department of Cardiothoracic Surgery, Walter Reed National Military Medical Center, Bethesda, MD

INTRODUCTION

- Toxic shock syndrome (TSS) is associated with vaginal rings and intrauterine devices, but there are no reports of infective endocarditis (IE) secondary to estradiol vaginal ring.
- Methicillin-susceptible *S. aureus* (MSSA) is the most common cause of TSS and IE in the United States and most developed countries.
- IE has an exceptionally high mortality rate of 15-20% in hospital and approximately 40% at 1 year even with early diagnosis and appropriate intervention.[1]

CASE PRESENTATION

- 57 year old female with history of hypertension presented with fever, fatigue, and nausea/emesis. Febrile, tachycardic, and hypotensive on exam with concern for sepsis; broad spectrum antibiotics started.
- High sensitivity troponin 38.7; creatinine 1.8; AST/ALT 148/175. Blood cultures MSSA positive within 8 hours.
- WBC increased from 6.3 to 28.3 despite antibiotics.
- Multi-organ failure in setting of new rash on palms and soles consistent with TSS and potentially IE.
- CT abdomen/pelvis suggestive of pessary in vaginal canal. Vaginal ring removed with right angle forceps; thick discharge in vaginal vault.
- TTE unremarkable; CT PET with hypermetabolism of mitral valve (MV) area and glenohumeral (GH) joint concerning for embolic phenomena secondary to IE; TEE with MV vegetation confirmed by cardiac CT.
- Patient with AMS; MRI brain reveals small infarct of left frontal lobe compatible with septic emboli.
- CT surgery consulted for definitive treatment given left sided IE caused by MSSA and recurrent emboli and persistent vegetations despite antibiotics.[1,2]
- MV repair performed without complication; patient discharged on 6 weeks of antibiotics and ID follow up.

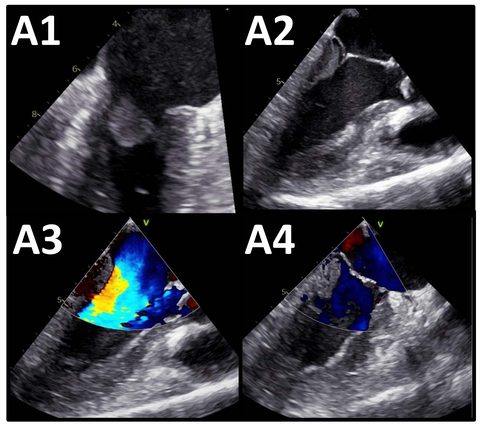

Image A: TEE notable for MV vegetation (A1) involving lateral left ventricle wall (A2); increased mitral inflow (A3) adjacent to vegetation; preservation of sub-valvular space below P2 leaflet (A4).

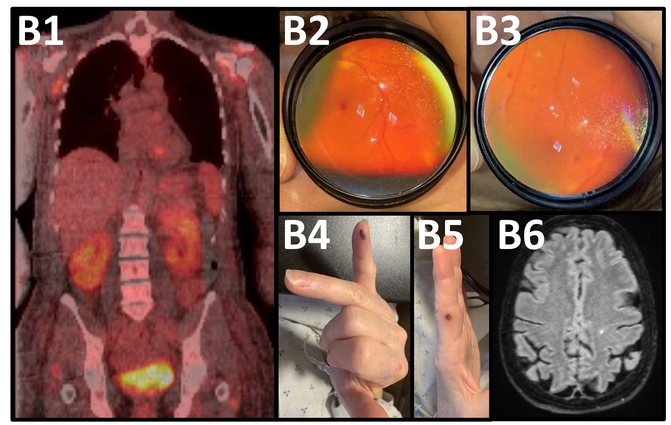

Image B: Hypermetabolism of MV and left GH joint on CT PET (B1); immunologic phenomena with Roth spots (B2,B3) and Osler nodes (B4,B5) on exam; embolic phenomena with intracranial infarct in posterior left frontal lobe on MRI (B6).

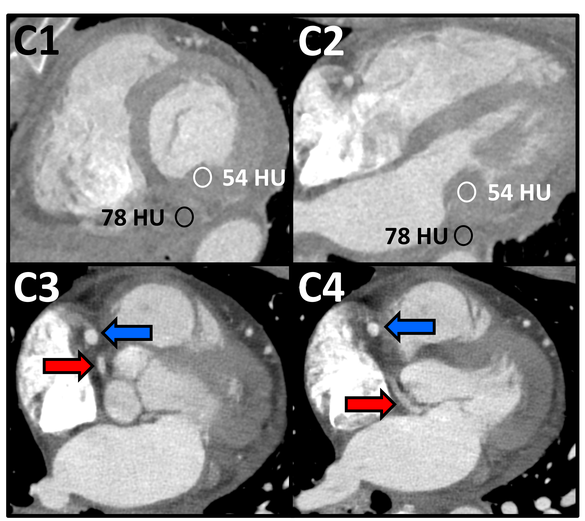

Image C: CT in short (C1) and parasternal long axes (C2) demonstrating radiodensity difference between vegetation and myocardium; anomalous LCx (*red arrow*) with posterior takeoff of RCA (*blue arrow*) and retro-aortic course (C3,C4).

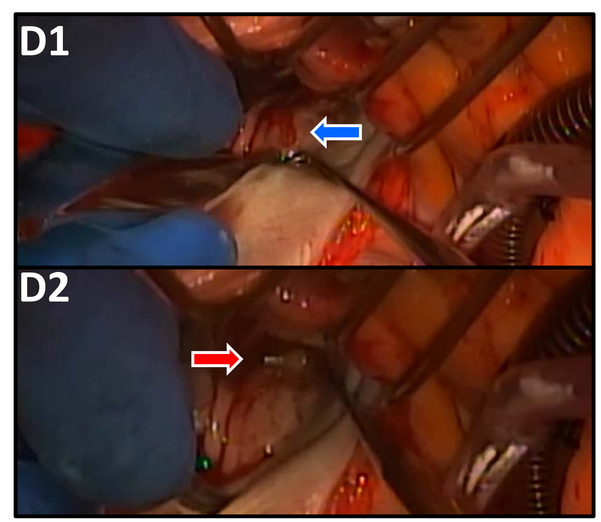

Image D: Friable tissue adherent to the P2 leaflet (*blue arrow*) that was debrided intraoperatively (D1); large vegetation (*red arrow*) below the annular level of the MV exposed with right angle probe (D2).

DISCUSSION

- Prior studies have noted cases of TSS but not IE associated with long acting hormonal therapy, even in women with known cardiovascular conditions.[3]
- Persistent bacteremia should create a high level of suspicion for IE and Modified Duke Criteria should be utilized to routinely re-evaluate patients with suspected IE as exam findings may change over time.[1,4] Multiple imaging modalities may be needed to confirm diagnosis.[4]
- Early recognition and treatment of IE may prevent embolic events and stroke, heart failure, and intracardiac abscess associated with IE.[1]
- Source control with surgical intervention is definitive treatment in the setting of persistent bacteremia and IE, specifically in instances of left sided IE with MSSA.[1,2,4]
- Medical and surgical management should be coordinated using a multi-disciplinary approach via Heart Team consisting of cardiology, CT surgery, and ID specialists.

CONCLUSIONS

- This case highlights a novel case of IE in the setting of an infected vaginal ring which has not been previously reported in the literature.
- Rapid diagnosis of IE using multiple imaging modalities and multi-disciplinary team leads to earlier definitive treatment and improved mortality.[5]

REFERENCES

1. Nishimura RA, et al. 2014 AHA/ACC Guideline for the Management of Patients with Valvular Heart Disease: a Report of the American College of Cardiology/American Heart Association Task Force on Practice Guidelines. J Am Coll Cardiol 2014; 63:e57–185.
2. Pettersson GB, Coselli JS, Hussain ST, et al. 2016 The American Association for Thoracic Surgery (AATS) Consensus Guidelines: Surgical Treatment of Infective Endocarditis: Executive Summary. J Thorac Cardiovasc Surg 2017; 153:1241-1258.
3. Quyen V, et al. Efficacy and Safety of Long-Acting Reversible Contraception in Women With Cardiovascular Conditions. Am J Cardiol 2016; 117(2):302-4.
4. Chambers HF, Bayer AS. Native-Valve Infective Endocarditis. N Engl J Med. 2020 Aug 6;383(6):567-576.
5. Chirillo F, Scotton P, Rocco F, et al. Impact of a Multidisciplinary Management Strategy on the Outcome of Patients with Native Valve Infective Endocarditis. Am J Cardiol. 2013;112(8):1171-6.

Contact information for the authors:
T Looney, MD at todd.l.looney.mil@mail.mil; E Anderson, MD at erik.l.anderson4.mil@mail.mil